

# Predicting the difficult airway



SM Crawley MBChB FRCA  
AJ Dalton MBChB FRCA

## Key points

Failure to assess and identify predicted difficulty in airway management and the failure to incorporate these findings into a management strategy can contribute to a poor outcome.

A perfect airway assessment tool does not exist and unanticipated difficulty will still occur.

Using multiple tests to predict difficulty in airway management is a better predictor than any single test used in isolation.

Airway assessment forms the first part of any airway management strategy, leading to planning of the drugs, equipment, and techniques to be used.

Assessing for a difficult airway at extubation is equally important.

The difficult airway (DA) has been defined as 'the clinical situation in which a conventionally trained anaesthesiologist experiences difficulty with face mask ventilation of the upper airway, difficulty with tracheal intubation, or both'.<sup>1</sup> A more complete definition would include airway instrumentation (e.g. with supraglottic airway devices), direct tracheal access, and consideration of the airway at extubation.

The 4th National Audit Project found that failure to assess for and identify potential difficulty, or the application of poor judgement in management planning, may contribute to a poor outcome.<sup>2</sup> Airway assessment must go beyond carrying out a series of bedside tests; it must attempt to identify problems in each facet of airway management and incorporate these logically into a strategy. This should take into account anatomical variations, airway pathology, and previous strategies. Of great importance is the consideration of how these factors may impact on the likely success of any given technique or equipment used. The skills of the anaesthetist and the equipment available must also be accounted for.

Before anaesthesia, the anaesthetist should be able to answer key questions.

- Will I be able to mask ventilate?
- Will I be able to perform laryngoscopy, directly or indirectly?
- Will I be able to intubate this patient?
- Is there a significant aspiration risk?
- If I predict difficulty, should I secure the airway awake?
- Can I access the cricothyroid membrane if needed?
- How will the airway behave at extubation?

## Clinical history

Medical records and documentation regarding previous airway management are of great importance. In the absence of new or significantly worsening pathology, it is of value to have feedback from a previous anaesthetist with regard to the ease of mask ventilation, ease of direct and/or indirect laryngoscopy, and with what airway

devices they had success or failure. In all cases, whether easy or difficult, it is useful to record this information for the benefit of future colleagues. The patient may offer information directly, with some having copies of an Airway Alert Form (available from DAS website). Details may be available from general practitioners, who may have been informed of previous difficulties.

The history of chronic diseases such as rheumatoid arthritis, ankylosing spondylitis, and diabetes mellitus with limited joint mobility should be noted. Rare syndromes associated with DA exist, including Pierre-Robin, Klippel-Feil, and Treacher-Collins. Recent acute respiratory tract infections can increase the possibility of laryngospasm and bronchospasm.

Questions that elicit and quantify aspiration risk and presence and degree of obstructive sleep apnoea (OSA) should be posed; both are more common in the obese population. Any new or worsening airway pathology must also be considered as it will produce a new clinical picture that may require a different approach. Information on the presence and nature of stridor, degree and progression of hoarseness/voice change, dysphagia, secretions, and ability to lie flat should be sought. With trauma, assessment should be directed to the onset of swelling, pain, trismus, and the time lapsed since the injury (e.g. facial fractures). Chemical and thermal injury to the airway requires prompt and careful assessment as mucosal oedema can develop rapidly. While not strictly part of the clinical history, the location must also be considered, as the incidence of DA is increased up to 10-fold in emergency departments and intensive care units. Undertaking airway management in these settings can be predictive of difficulty in itself, due to the nature of patients who require airway intervention there.

## Clinical examination

Patient examination assessing for obesity, prominent chest/breasts, beards, and obvious external signs of head and neck pathology are easily carried out. Many more airway-specific tests that

### SM Crawley MBChB FRCA

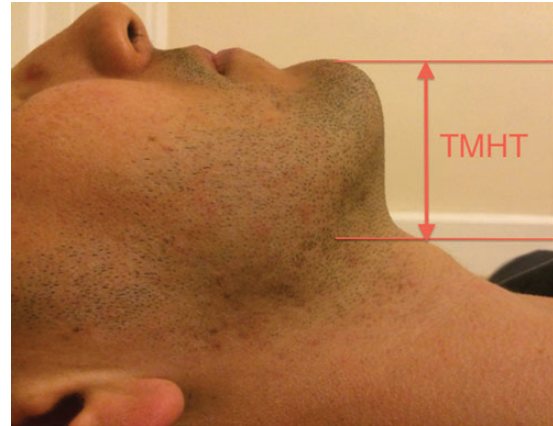
Consultant Anaesthetist  
Department of Anaesthesia  
Ninewells Hospital and Medical School  
Level 6  
Dundee DD1 9SY  
UK  
Tel: +44 1382 632175, 44 1382 632858  
Fax: +44 1382 644914  
E-mail: simoncrawley@nhs.net  
(for correspondence)

### AJ Dalton MBChB FRCA

Speciality Registrar in Anaesthesia and  
Critical Care  
Ninewells Hospital and Medical School  
Dundee  
UK

attempt to predict difficulty have been studied and publications are available throughout the literature. There is no ideal airway assessment tool that can be used, and the lack of statistical predictive power of individual airway tests is well accepted. However, they should heighten our awareness for the potential of difficulty and allow preparation for it. Documented recent airway management in the absence of new non-reassuring signs or pathology is as close as we have to a useful test, but this has flaws, not least individual operator bias.

Mouth opening ability is crucial to most airway interventions and is best measured as an inter-incisor gap. A distance of <3 cm is generally accepted as a non-reassuring sign, although some videolaryngoscopy (VL) blades require as little as 1.8–2 cm for insertion, while successful supraglottic device (SAD) use has been reported in patients with <2 cm mouth opening. The modified Mallampati classification is commonly applied and assesses the tongue size, oropharyngeal cavity size, and their relationship to each other. This is carried out with the patient sitting, opening their mouth, and protruding the tongue maximally, producing a score of 1–4, depending on anatomical structures seen. Class 3 (where the soft palate and base of the uvula are seen) and 4 (where only the hard palate is seen) are attributed to difficulty in mask ventilation and difficult laryngoscopy (DL), but it has poor inter-observer reliability and positive predictive value (PPV) if used alone. Thyromental distance (TMD) and sternomental distance (SMD) are commonly measured. TMD is the distance from the upper border of the thyroid cartilage to the tip of the jaw, measured with the head extended with a distance of <6.5 cm being associated with DL; while in SMD, the distance from the sternal notch to the tip of the jaw with the head extended, a distance of <12.5 cm, is similarly associated. These distances are best measured with rulers or measuring tape, as the use of finger-breadths is variable and less accurate. TMD can be modified by calculating its ratio with height (RHTMD), with this being a more accurate predictor of DL.<sup>3</sup> A ratio of neck circumference to TMD (NC/TMD) has been studied, with a ratio of >5.0 proposed as an improved predictor compared with standard measures.<sup>4</sup> Thyromental height (TMHT) (Fig. 1) is a recently described anatomical measure with potentially more accurate predictive capability with 83% sensitivity and 99% specificity, but it remains to be validated in large-group studies.<sup>5</sup> Jaw protrusion and the upper lip bite tests both assess temporomandibular joint function and prognathic ability, taking into account the prominence of maxillary teeth. Dentition, particularly dentures, loose dental work, and the presence of single maxillary incisors, should be noted. Neck movement should be assessed as part of the patient's ability to achieve the 'sniffing position' (cervical flexion and atlanto-occipital extension) for mask ventilation and laryngoscopy, but also for optimal positioning in extension for neck access, if required in an emergency. The identification of the cricothyroid membrane at this point in the examination is useful. Finally, it is useful to palpate the submandibular space. Tissue changes, due to irradiation, neck infection, or burns, mean that displacement of the tongue into the submandibular space during laryngoscopy may not occur easily, thus increasing difficulty.



**Fig 1** TMHT is a measure of vertical height from the anterior border of the thyroid cartilage and the anterior border of the mentum. A cut-off of 50 mm allows optimal sensitivity and specificity when using this test.

Non-compliant tissue restricts the effectiveness of basic airway manoeuvres resulting in difficult mask ventilation (DMV). Asking patients to protrude their tongue may demonstrate this limited mobility.

Airway assessment should utilize multiple components to increase their usefulness; however, airway tests even in combination are not diagnostic. Several multivariate scoring systems have been produced, including the Wilson Score, MTAC, and the Simplified Airway Risk Index (SARI). These assess multiple predictors, with summed or weighted scores, with increased PPVs compared with single tests in isolation. It is not fully known if using several individual tests in an unspecified manner is less predictive than structured objective scoring systems. A large multicentre Danish (DIFFICAIR) trial, utilizing SARI, is currently examining this, while a recent study comparing a very comprehensive assessment, utilizing 11 individual airway features, did not show a significantly improved detection rate for DA.<sup>6</sup>

We acknowledge that the aforementioned examinations are overwhelming and excessive for most patients. However, we recommend that at a minimum, some form of systematic approach to airway assessment and documentation should be performed for all patients.

## Clinical investigations

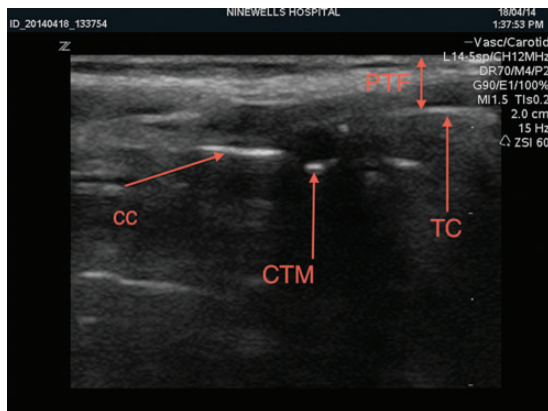
### Radiographs

Plain radiographs can play a part in airway assessment, although not routinely. A reduction in space (<5 mm) between the C1 spinous process and the occiput, seen on a lateral neck radiograph taken in a neutral position, is recognized as an indicator of difficult intubation. Foreign bodies may be visible, allowing identification of the nature and level of obstruction and the size of any accessible airspace around it. A chest X-ray may demonstrate distal obstruction, airway collapse, or gas trapping. In other pathologies, soft tissue swelling and tracheal compression/deviation may be noted and warrant further investigation with CT or nasendoscopy. Orthopantomograms

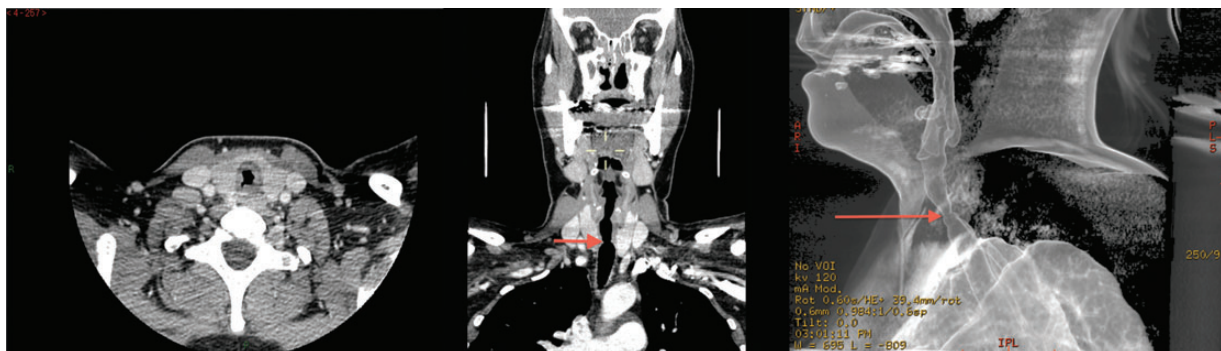should be examined. The presence of facial fractures, including mandible fractures, can increase the likelihood of both DMV and laryngoscopy due to anatomical disruption and tissue swelling. Intra-oral bleeding can hinder glottic visualization, particularly during indirect VL and fiberoptic techniques. Zygomatico-maxillary fractures should be assessed for fracture impingement on the coronoid process, as any limitation of mouth opening will not improve with induction of anaesthesia and paralysis.

## Ultrasound

Ultrasound use for the detection of large midline vasculature in assessing suitability for percutaneous tracheostomy is well established and its use as an aid for both identification of the cricothyroid membrane (Fig. 2) and for the procedure itself is gaining popularity. Proposals have also been made for its use in predicting difficult intubation by measurement of various parameters, including tongue thickness, pre-tracheal fat at vocal cord level (Fig. 2), and the ability to visualize the hyoid bone with sublingual ultrasound, but these require larger scale validation.<sup>7,8</sup>



**Fig 2** Neck ultrasound showing structures of cricoid cartilage (CC), membrane (CTM), and thyroid cartilage (TC). The amount of pre-tracheal fat (PTF) can also be estimated, which is associated with difficult intubation.



**Fig 3** Coronal CT slice, MPR, and 3D CT reconstruction showing significant subglottic stenosis (arrowed) secondary to granulomatosis.

## Computed tomography, MRI, and reconstructions

Computed tomography and MRI scans have improved the assessment of patients with complex airway pathology, although some anaesthetists may not feel comfortable with their interpretation. Joint discussion with the surgeon or radiologist is useful with regard to causes of pathology, level and severity of any stenosis, or any subglottic extension. MRI is useful for soft tissue pathology, but the ability of many patients to lie flat for prolonged periods can be limiting. Multi-planar reformations (MPR) in sagittal and coronal planes are more useful than coronal image slices in demonstrating stenosis, the degree of airway distortion, and in delineating airway anatomy (Fig. 3). Three-dimensional (3D) images and use of post-reconstruction processing software (e.g. OsiriX) can allow the creation of a virtual 3D endoscopy to aid education, but these are unlikely to replace conventional endoscopic examination.<sup>9</sup>

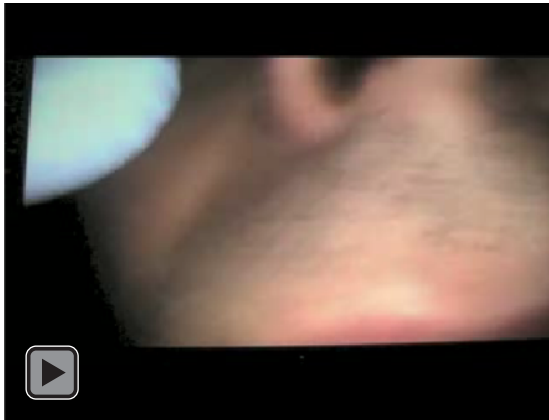## Nasendoscopy

Nasendoscopy (Fig. 4 and Fig. 5 online videos) is useful for examining the upper airway anatomy and identifying abnormalities, such as upper airway swelling/anatomy distortion, and the significance of any peri-glottic lesions. Nasendoscopy can be performed at a pre-assessment clinic, on the ward, or pre-induction in the operating suite. Information on the impact any lesion will have on laryngoscopy, flexible fiberoscopy, intubation, and even direct tracheal access can be gathered and incorporated into the plan. It is important to remember that airway patency is protected by pharyngeal tone in an awake patient, which will be reduced with induction of anaesthesia; therefore, normal nasendoscopy does not guarantee straightforward airway management once anaesthesia is commenced.

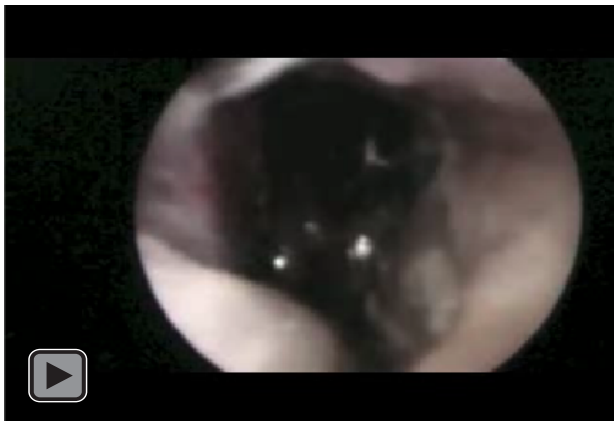## Predicting difficulty in mask ventilation

Mask ventilation is the most basic, and arguably most important, skill in airway management. Patients who have been identified as having DMV, or who are predicted to be difficult, are, or potentially are, at the highest risk in airway management. It is this facet of management that should influence our decision-making the most,





**Fig 4 online video** Normal nasendoscopy. A small septal deviation is present. If reading the pdf online, click on the image to view the video.



**Fig 5 online video** Abnormal nasendoscopy. Significant supraglottic soft tissue oedema affecting the valleculae, epiglottis, and both aryepiglottic folds. If reading the pdf online, click on the image to view the video.

potentially with consideration given to awake techniques. DMV can also be suggestive of difficulty in subsequent laryngoscopy.

DMV occurs in up to 5% of patients, and there are several factors that are known to be predictive of this. An early study highlighted five independent factors, allowing the mnemonic OBESE [Obese, Bearded, Elderly (>55 yr), Snorer, and Edentulous] to be used.<sup>10</sup> Further study of DMV added modified Mallampati class of 3 or 4, limited jaw protrusion, and the male sex. Neck irradiation is the most significant predictor of impossible mask ventilation, defined as an inability to achieve gas exchange despite the use of adjuncts, multiple providers, and neuromuscular block, as it causes development of fibrotic non-compliant tissue affecting the airway.<sup>11</sup>

BMI itself is not a very useful predictor, although it can be a marker for potential oxygenation issues (due to reduced FRC) and increased aspiration risk. In predicting DA, the actual distribution of body fat should be considered, with fat deposition in the parapharyngeal tissues increasing airway collapsibility, predisposing to OSA. This is seen more in android pattern obesity with distribution of

adipose tissue around the trunk, upper body, and neck. The increased fat deposits in neck tissue can further narrow the airway. OSA, snoring without apnoea, and increasing neck circumference, above 40 cm, are associated with DMV.<sup>11</sup> The probability of DMV increases with increasing neck circumference.

### Predicting difficulty in airway instrumentation

Nasal passages are accessed for nasopharyngeal airway insertion as part of rescue in failing airway management, alleviation of upper airway obstruction, or for nasal intubation. Insertion can cause trauma and bleeding. It is important to be aware of septal deviation, polyps, or clotting abnormalities that may increase these complications and the overall difficulty, by adding blood to the airway.

Limitation in mouth opening will influence the ability to insert almost all devices. Assessment of inter-incisor gap must be taken into account with regard to the choice of device to be used, including rescue devices. Slimmer profile VL blades and SADs can pass through inter-incisor gaps of <3 cm normally required for Macintosh blade use. Anaesthetists must have knowledge of available VL devices and their limitations when selecting to use this approach rather than a fibreoptic technique, in patients with severely limited mouth opening. A narrow or high arching palate will also reduce space for the blade in the oropharynx. Barrel chests and large breasts can complicate laryngoscope insertion, although these can be overcome by using a ‘ramping’ position and device selection. Limited neck extension and relative or absolute retrognathia will alter the angle in which devices can be inserted and hinder their use, so indirect laryngoscopy may be considered advantageous. It is important to remember that the application of cricoid pressure can reduce achievement of optimal glottic visualization and can be removed under direct vision to assess for potential improvement in view. Cricoid pressure can also prevent successful rescue SAD insertion and it should be removed if difficulty is encountered.

Direct access to the trachea is required for rescue in a ‘can’t intubate, can’t ventilate’ (CICV) situation, but can also be part of a planned pre-induction technique during complex head and neck surgery or when there is an anticipated risk of emergent airway obstruction. Difficulty will be encountered in the presence of obesity with anterior neck fat, irradiated neck tissues, previous tracheostomy, thyroid or neck masses with/without tracheal deviation, limited extension, short SMD, and in fixed neck flexion deformities. It is more difficult to palpate and identify anatomical landmarks in female patients and young children. Preoperative marking, in those with predictable difficulty, ideally under ultrasound guidance, could be considered useful.

### Predicting difficulty in laryngoscopy

DL can become traumatic laryngoscopy, itself increasing difficulty, so it is important to develop a strategy that best facilitates first-attempt



intubation success while adhering to guidelines after any failure or unanticipated difficulty.

Anatomical factors, affecting insertion of the laryngoscope, as described above will clearly impact on the final view obtained, particularly small inter-incisor gap, prominent incisors, large tongue, and retrognathia. Decreased TMD, SMD, and TMHT are all attributed and may be suggestive of an anterior larynx, relative to the line of sight. Modified Mallampati class 3 or 4 is predominant in those with DL due to an imbalance in the tongue and oral cavity relationship. Large neck circumference, increased pre-tracheal soft tissue, and occipital tissue are associated with difficulty, the latter impacting on achieving optimal positioning through limitation of neck extension. Pathologies such as epiglottitis, lingual tonsil hyperplasia, and Ludwig's angina are well documented as contributing to difficult or impossible laryngoscopy.

A model has been proposed by Greenland<sup>12</sup> that considers multiple anatomical features, their interactions with each other, and the impact on practical direct laryngoscopy. It considers the volume and compliance of submandibular tissues; TMJ dysfunction causing reduced mouth opening or failure of mandibular protrusion; relative tongue volume; and both absolute and relative retrognathia. These factors will impact on the ability to displace tissue into the submandibular space and impede anterior movement of structures during laryngoscopy, all of which will influence the degree of glottic visualization. Pathology within the airway space (e.g. tumour or pharyngeal adipose tissue deposits) and any restriction of occipito-Atlanto-axial motion, with the ability to achieve optimal positioning ('sniffing' or 'ramped'), are incorporated.

## Predicting difficulty in intubation

Difficulties with intubation may still be encountered despite straight-forward direct or indirect laryngoscopy. A reduction in space within the oropharynx may not allow easy tracheal tube manipulation. Laryngeal tumours, vocal cord palsies, and subglottic stenosis will impact on technique and equipment choice, particularly in relation to tracheal tube sizing or suitability for awake fibroscopy. The presence of stridor with or without the presence of respiratory distress is a major risk factor and should alert the anaesthetist to these potential pathologies. The rapidity of the onset of symptoms and degree of respiratory distress will dictate what, if any, further investigation can be undertaken.

## Predicting difficulty in extubation

In 2012, the Difficult Airway Society published extubation guidelines, which have highlighted extubation as a vitally important stage in patient management.<sup>13</sup> Airway obstruction is the most common cause for early postoperative re-intubation, frequently due to laryngeal oedema. The behaviour of the postoperative airway is influenced by any trauma induced by attempts to secure it initially, and by any residual effect of general anaesthetic agents, opiates, inadequately reversed neuromuscular blocking drugs, or airway local

anaesthesia. The continuing effect of these drugs on airway reflexes and respiratory drive must be considered in all cases. Particular attention should be paid in obese patients, who are at increased risk of postoperative airway complications and desaturation, along with those patients undergoing airway surgery, head and neck surgery, and those maintained in Trendelenburg or prone positions or with prolonged intubation.

## Conclusions

Airway assessment is a crucial part of patient assessment before anaesthesia. Proper utilization of these tests in combination, and logical consideration of *how* they may manifest as potential difficulty, is key to planning the techniques that may help minimize this predicted difficulty and therefore facilitate a safe anaesthetic. No ideal mode of assessment exists, and unanticipated difficulty will still occur from time to time. Documentation and communication of any encountered difficulty is essential to aid future management. Extubation remains an important part of an airway strategy, and this should be considered both before operation and again intraoperatively to ensure the original plan remains suitable. Management of airway pathology can be enhanced with the use of radiology, MPR, and nasendoscopy, with the latter accessible to every anaesthetist.

## Online videos

The videos associated with this article can all be viewed from the article in *CEACCP* online.

## Declaration of interest

None declared.

## References

1. Practice guidelines for management of the difficult airway; an updated report by the American Society of Anaesthesiologists Task Force on Management of the Difficult Airway. *Anesthesiology* 2003; **98**: 1269–77
2. Cook TM, Woodall N, Frerk C. 4th National Audit Project of the Royal College of Anaesthetists and the Difficult Airway Society: Major complications of airway management 2011. Available from <http://rcoa.ac.uk/nap4>
3. Schmitt JH, Kirmse M, Radespiel-Troger M. Ratio of patients height to thyromental distance improves prediction of difficult laryngoscopy. *Anaesth Intensive Care* 2002; **30**: 763–6
4. Kim WH, Ahn HJ, Lee CJ et al. Neck circumference to thyromental distance ratio; a new predictor of difficult intubation in obese patients. *Br J Anaesth* 2011; **106**: 743–8
5. Etezadi F, Ahangari A, Shokori H et al. Thyromental height: a new clinical test for prediction of difficult laryngoscopy. *Anesth Analg* 2013; **117**: 1347–51
6. Cattano D, Killoran PV, Iannucci D et al. Anticipation of the difficult airway: preoperative airway assessment, an educational and quality improvement tool. *Br J Anaesth* 2013; **111**: 276–85
7. Hui CM, Tsui BC. Sublingual ultrasound as an assessment method for predicting difficult intubation: a pilot study. *Anaesthesia* 2014; **69**: 314–20

8. Erzi T, Gewurtz G, Sessler DI *et al.* Prediction of difficult laryngoscopy in obese patients by ultrasound quantification of anterior neck soft tissue. *Anaesthesia* 2003; **58**: 1111–4
9. Beser M, Gultekin E, Yener M, Zeybek E, Oner B, Topcu V. Detection of laryngeal tumours and tumoral extension by multislice computed tomography-virtual laryngoscopy (MSCT-VL). *Eur Arch Otorhinolaryngol* 2009; **266**: 1953–8
10. Langeron O, Masso E, Huraux C *et al.* Prediction of difficult mask ventilation. *Anesthesiology* 2000; **92**: 1229–36
11. Kheterphal S, Martin L, Shanks AM, Tremper KK. Prediction and outcome of impossible mask ventilation: a review of 50,000 anaesthetics. *Anesthesiology* 2009; **110**: 891–7
12. Greenland KB. A proposed model for direct laryngoscopy and tracheal intubation. *Anaesthesia* 2008; **63**: 156–61
13. Popat M, Mitchell V, Dravid R, Patel A, Swampillai C, Higgs A. Difficult airway society guidelines for the management of tracheal extubation. *Anaesthesia* 2012; **67**: 318–40